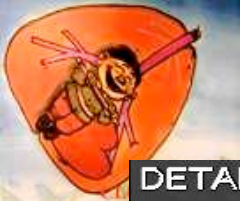



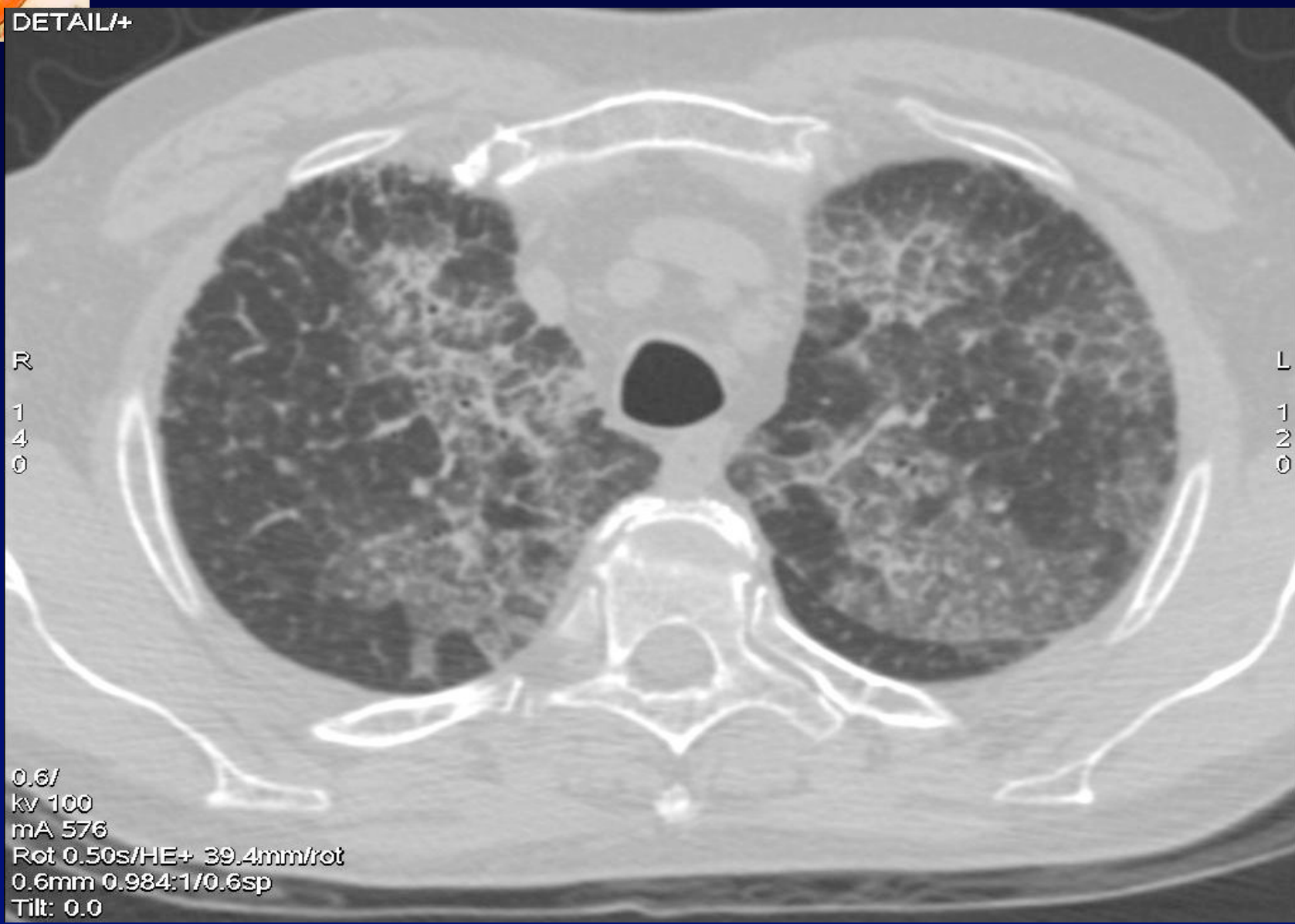
G.DURAND J.GIRON P.FAJADET

Homme de 40 ans

Dyspnée progressive puis marquée



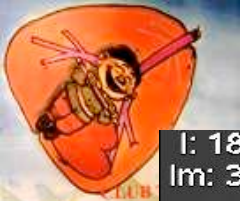DETAIL/+



R
1
4
0

L
0
2
1

0.6/
kv 100
mA 576
Rot 0.50s/HE+ 39.4mm/rot
0.6mm 0.984:1/0.6sp
Tilt: 0.0



I: 189.0
Im: 325

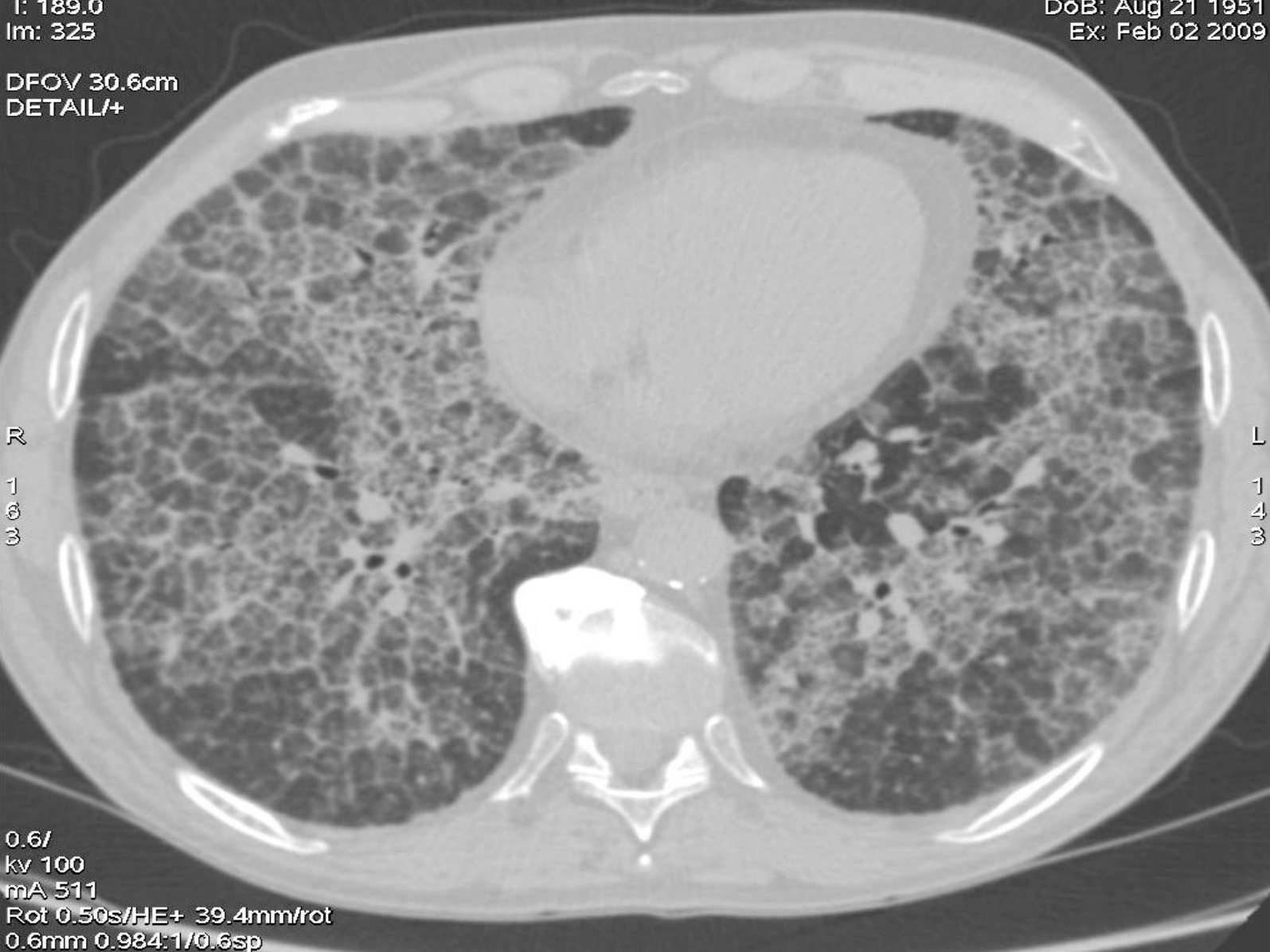DoB: Aug 21 1951
Ex: Feb 02 2009

DFOV 30.6cm
DETAIL/+

R
1
3
3

L
1
4
3

0.6/
kv 100
mA 511
Rot 0.50s/HE+ 39.4mm/rot
0.6mm 0.984:1/0.6sp





Se: 2
P: 35.7

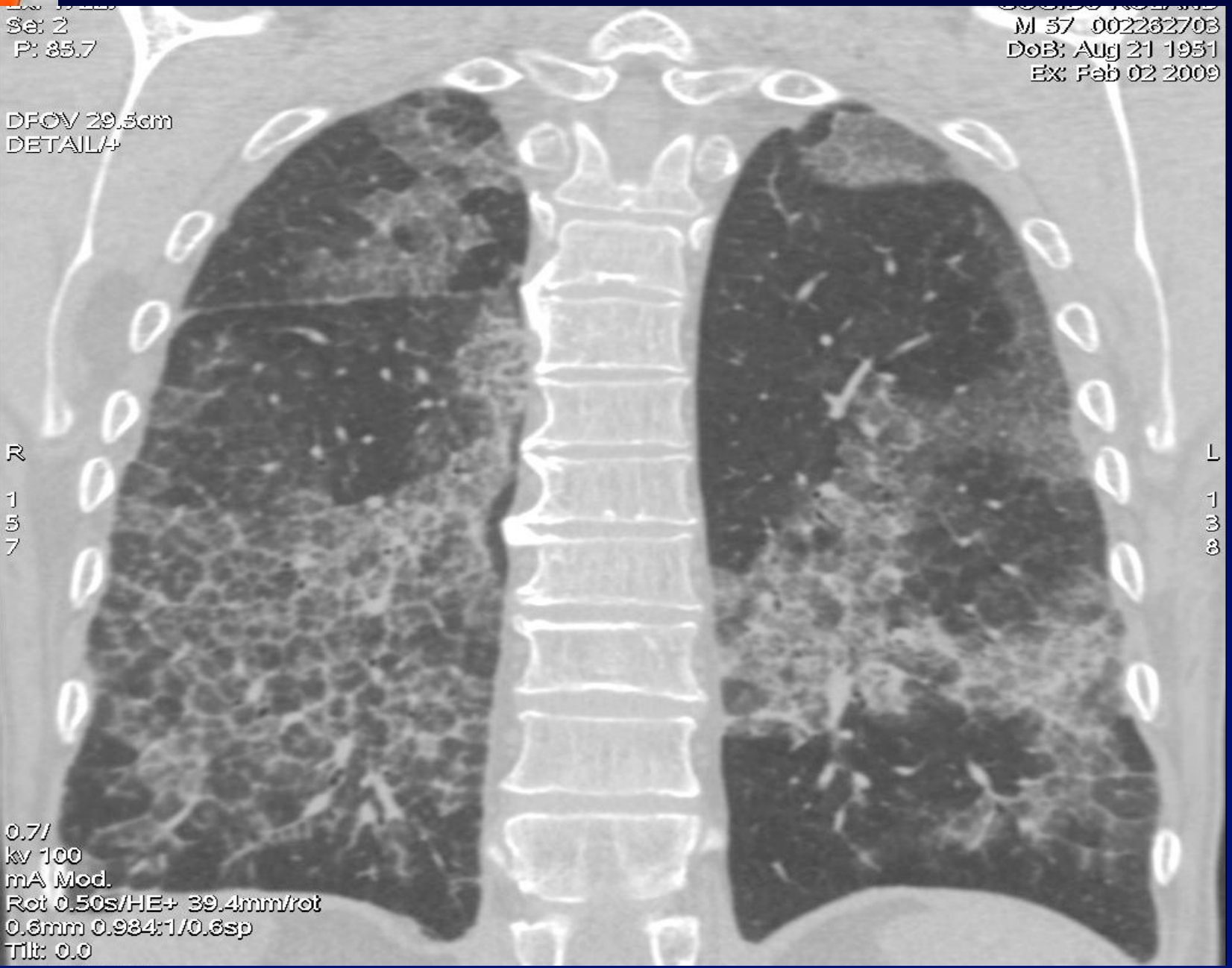M 57 002232703
DoB: Aug 21 1951
Ex: Feb 02 2009

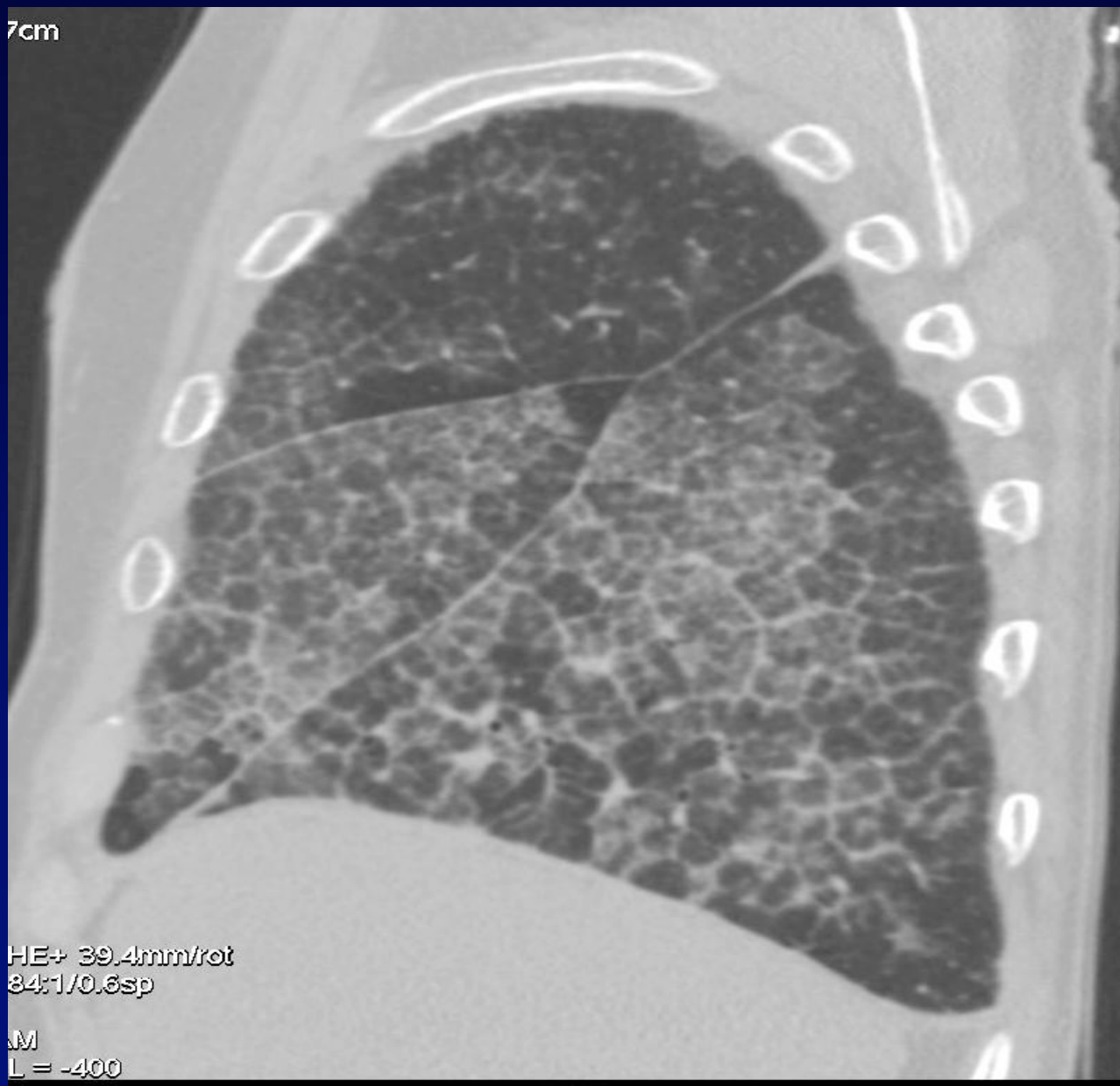DFOV 29.5cm
DETAIL+

R
1
5
7

L
1
3
8

0.71
kv 100
mA Mod.
Rot 0.50s/HE+ 39.4mm/rot
0.6mm 0.934:1/0.6sp
Tilt: 0.0





7cm

HE+ 39.4mm/rot
84:1/0.6sp

MM
L = -400



Diagnostic ?



I: 196.5
Im: 337

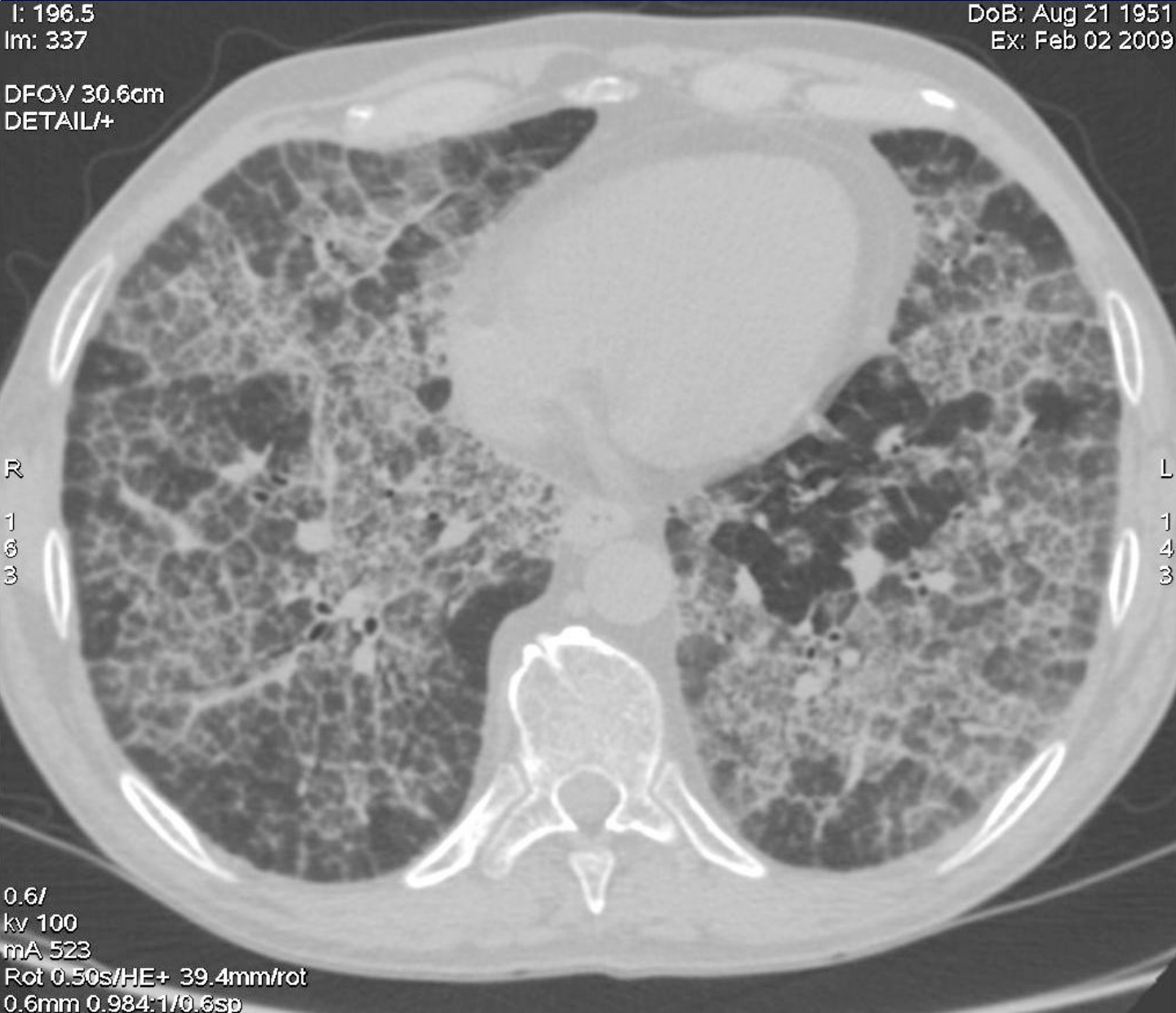
DoB: Aug 21 1951
Ex: Feb 02 2009

DFOV 30.6cm
DETAIL/+

R
1
6
3

L
1
4
3

0.6/
kv 100
mA 523
Rot 0.50s/HE+ 39.4mm/rot
0.6mm 0.984:1/0.6sp

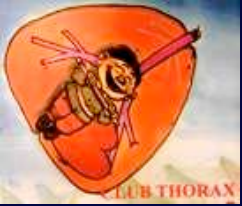



Diagnostic

« Crazy paving »

Gamme étiologique ...



Diagnostic

Dans ce cas :

Protéinose alvéolaire

Lavages Thérapeutiques méthode RAMIREZ